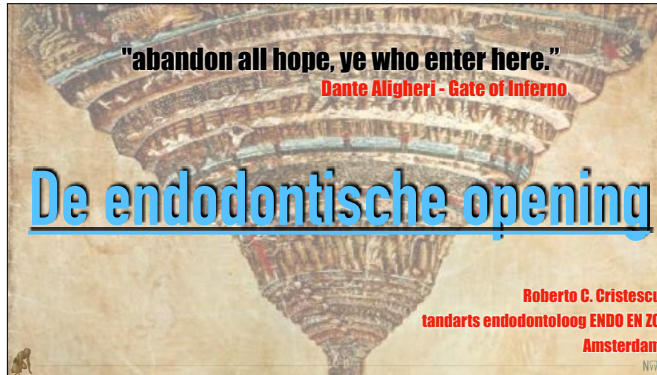
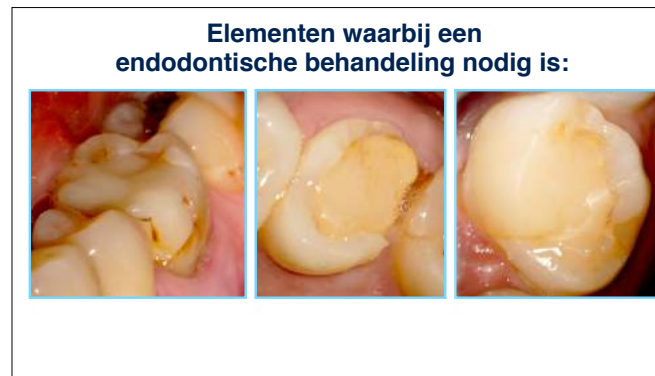
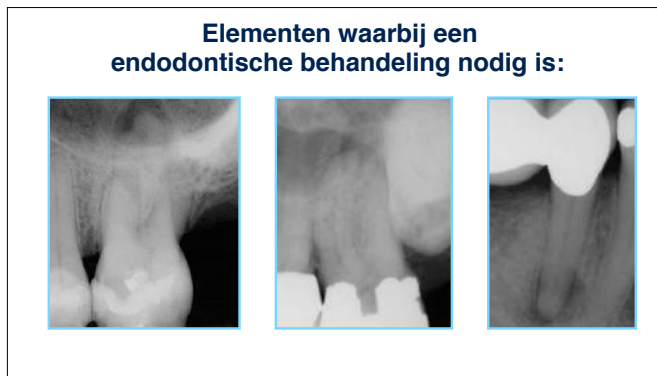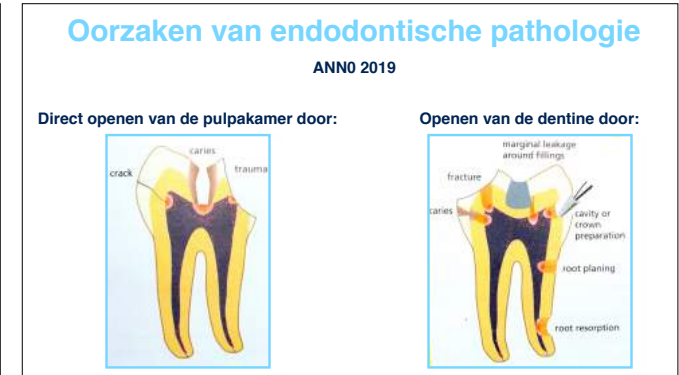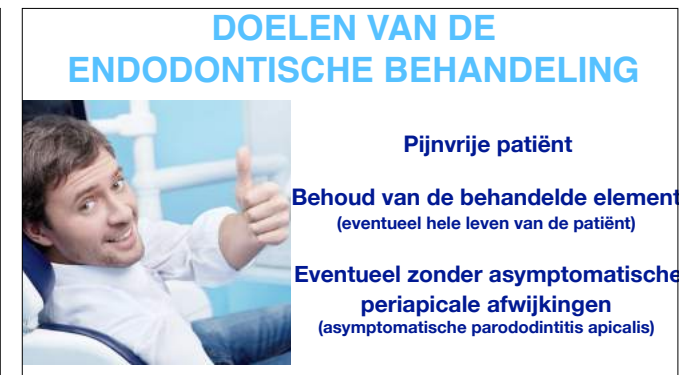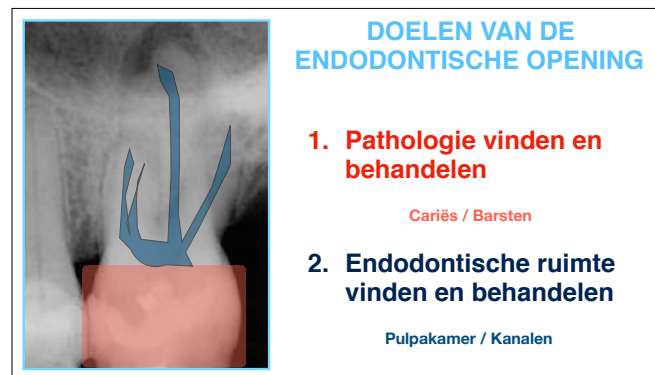


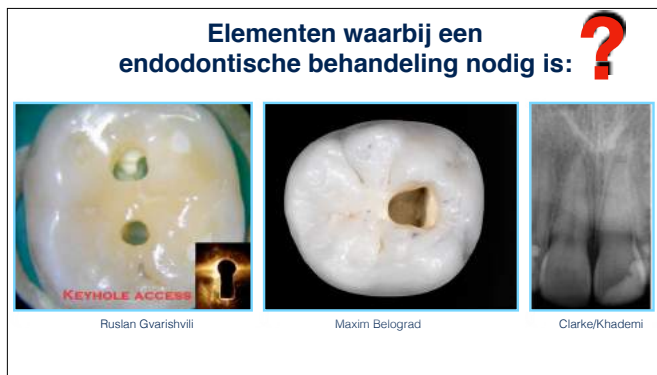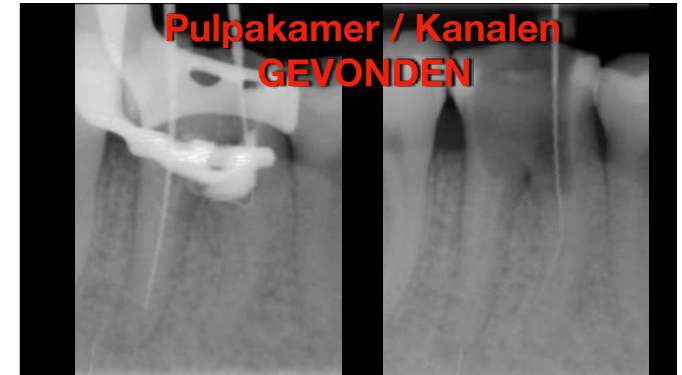
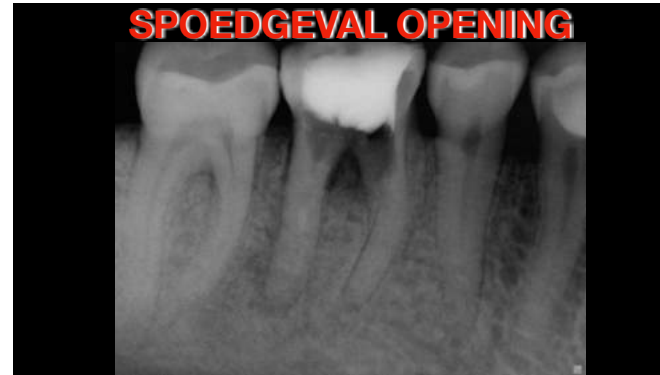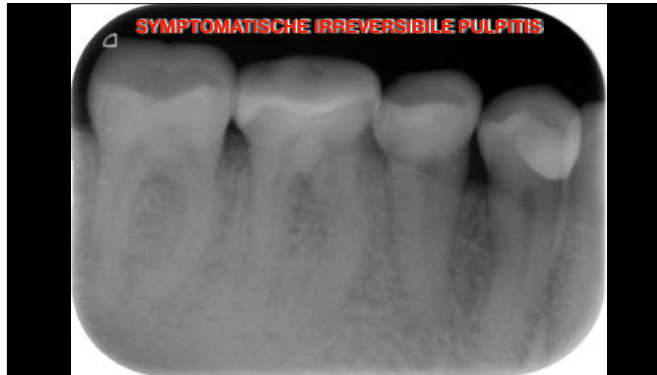Inhoud

1. Doelen van de opening / endodontische behandelingen
2. Instrumentarium
3. ZICHT / ZIEN : Dentine kleurkaart
4. Endodontische opening: Incisiven/ Premolaren/ Molaren

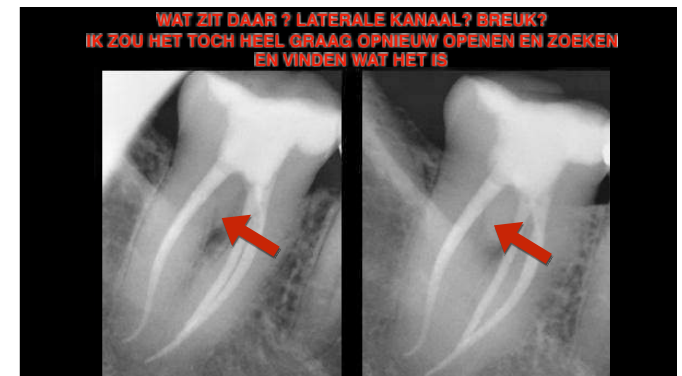
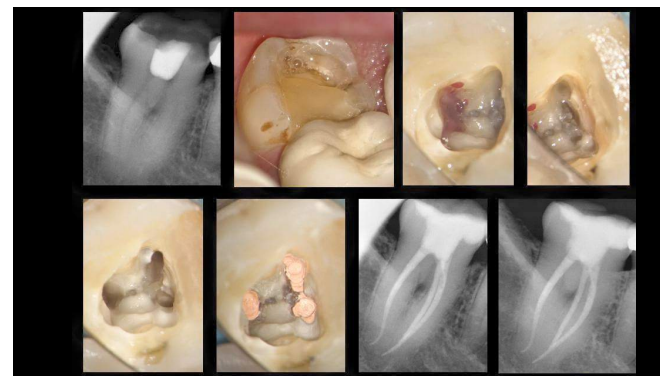

- ## VOLGORDE VAN VERWIJDEREN / OPOFFEREN
- AANGETAST WEEFSEL (CARIËS/BARSTEN)
 - RESTAURATIEVE MATERIELEN (AMALGAAM, COMPOSIT, PORCELEIN, GOUD)
 - GEZOND WEEFSEL





VOORKOMEN IATROGENISCHE SCHADE



DOELEN VAN DE ENDODONTISCHE BEHANDELING



Pijnvrije patiënt

Behoud van de behandelde element
(eventueel hele leven van de patiënt)

Eventueel zonder asymptomatische periapicale afwijkingen (asymptomatische parodontitis apicalis)


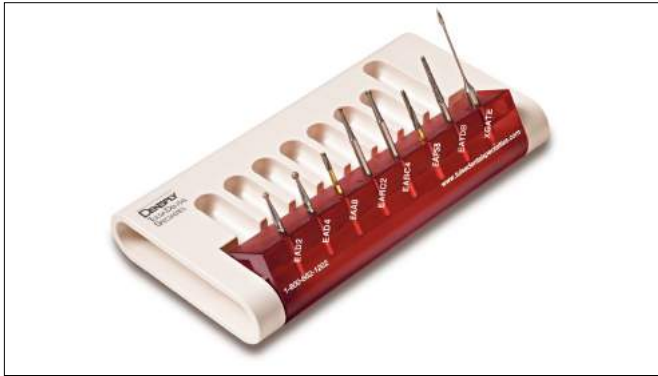
IS HET EEN ENDODONTISCH SUCCES ?

1. ENDODONTISCHE KLACHTEN? NIET

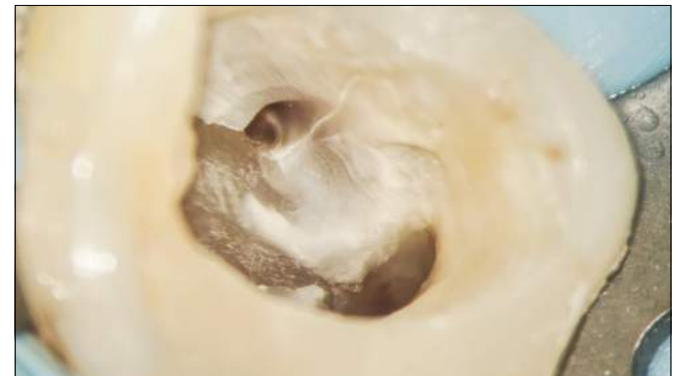
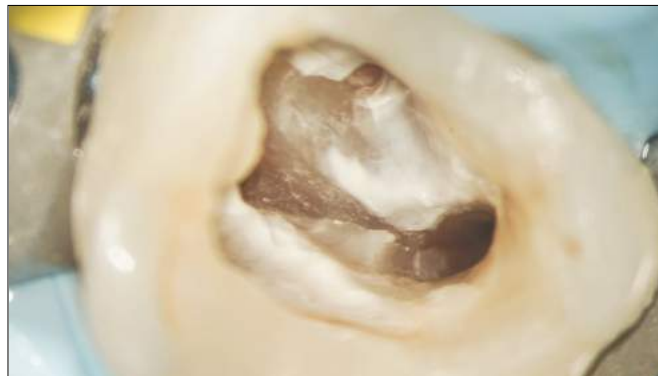
2. HOE OUD IS DE BEHANDELING? 31 JAAR

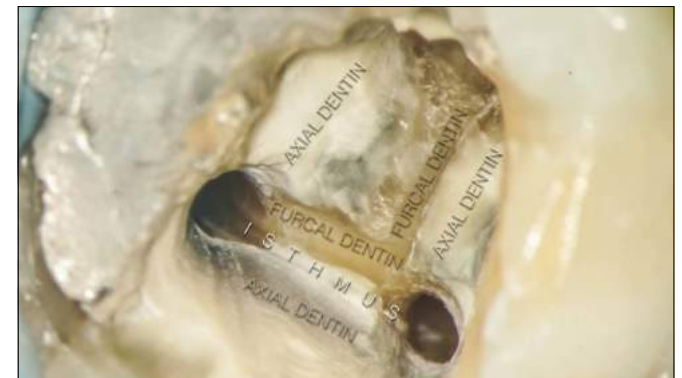
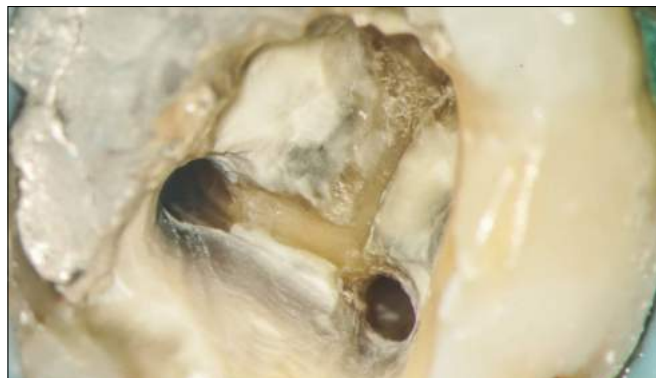
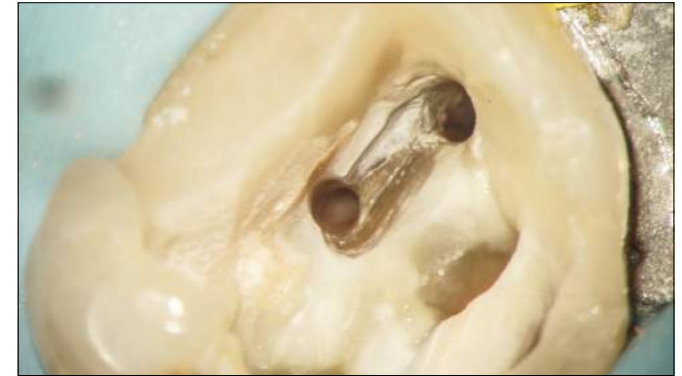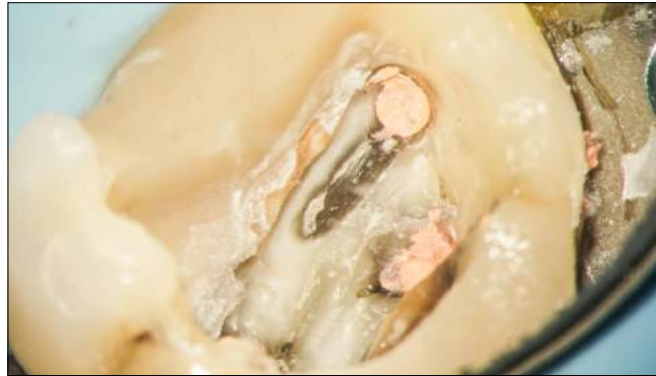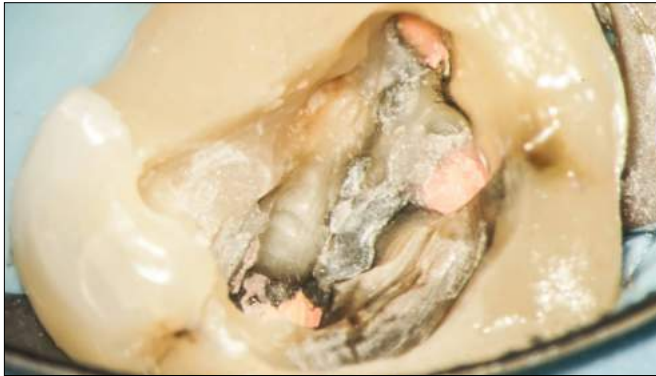INSTRUMENTARIUM

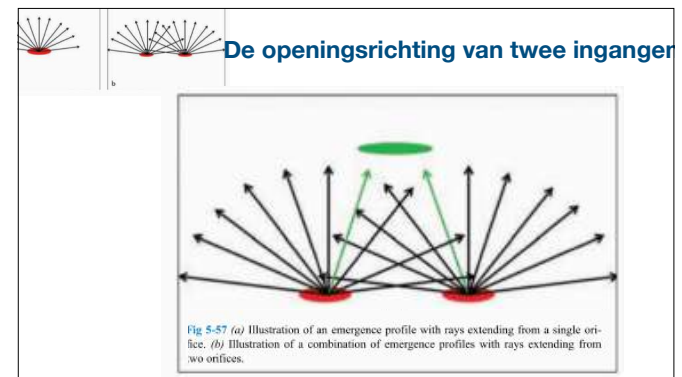
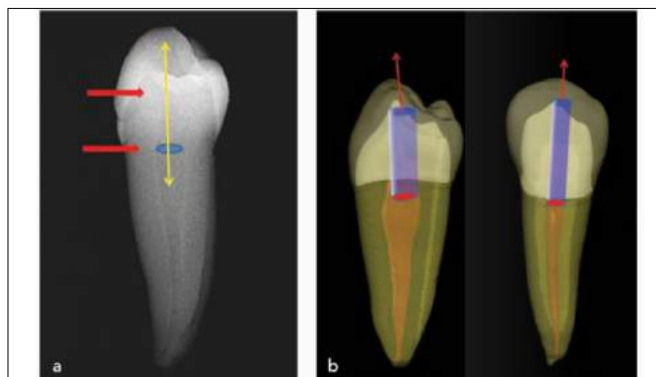


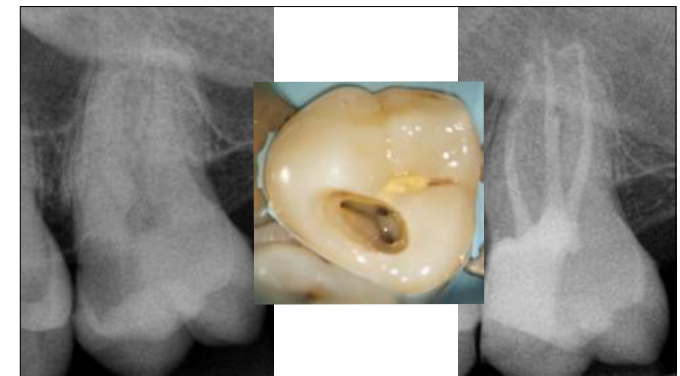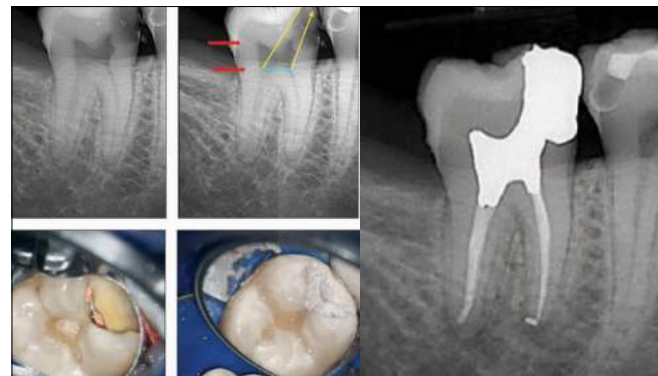
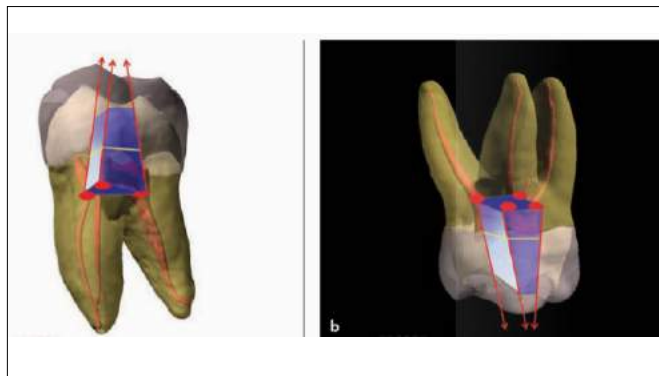
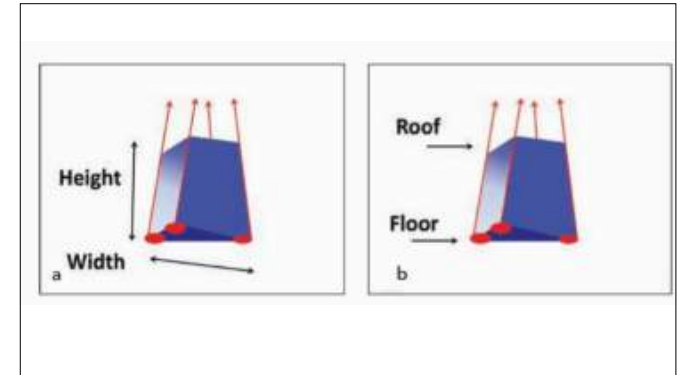
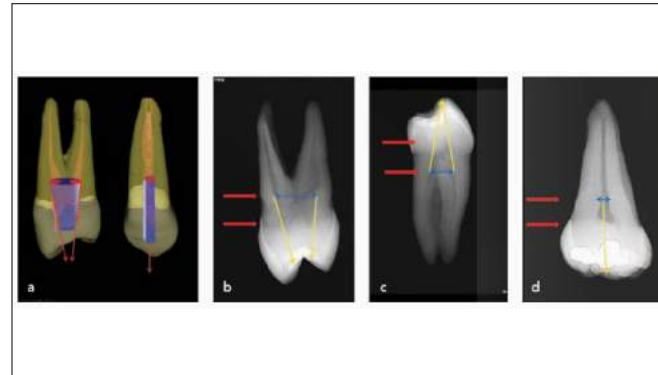
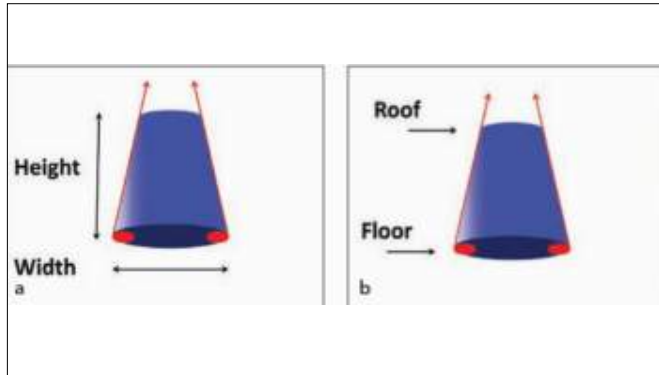
DENTINEKAART



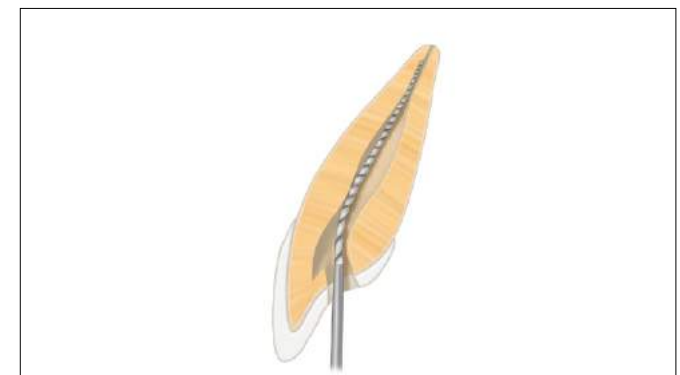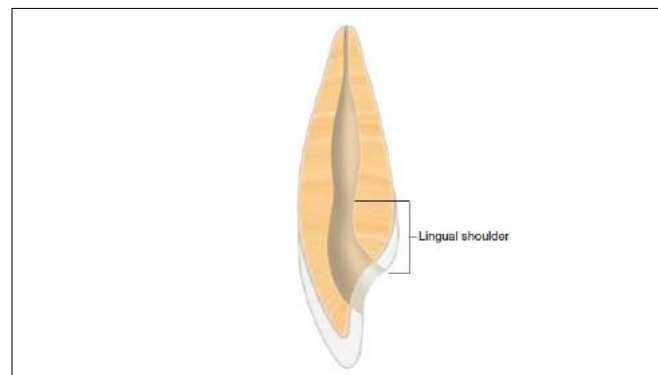


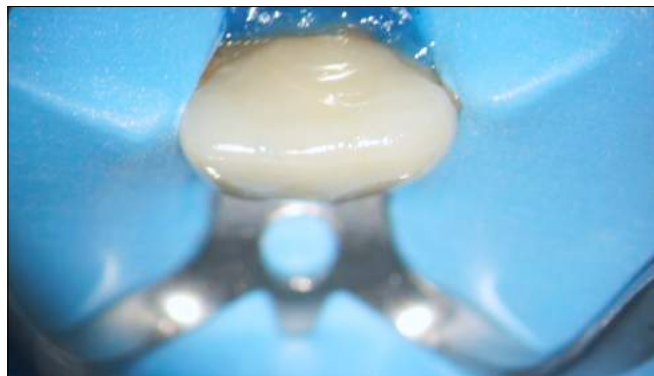
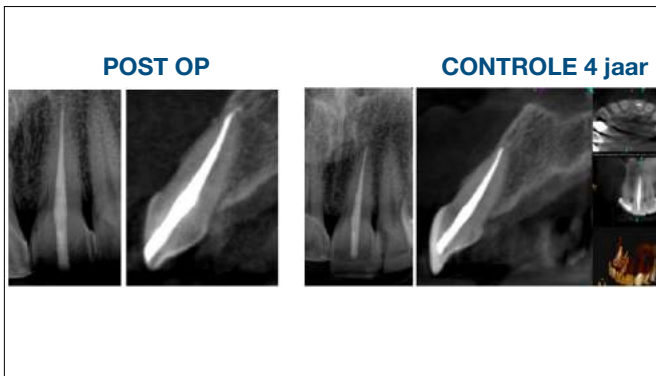
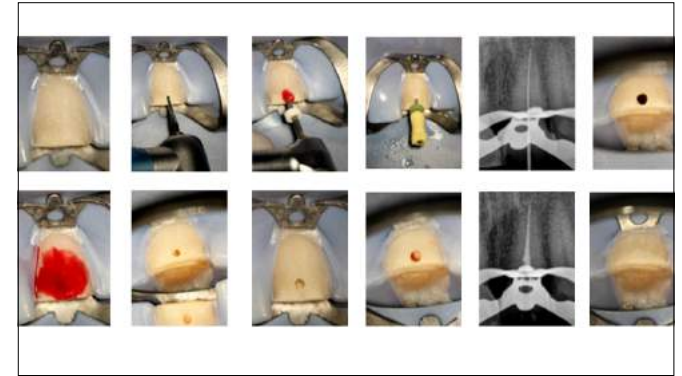
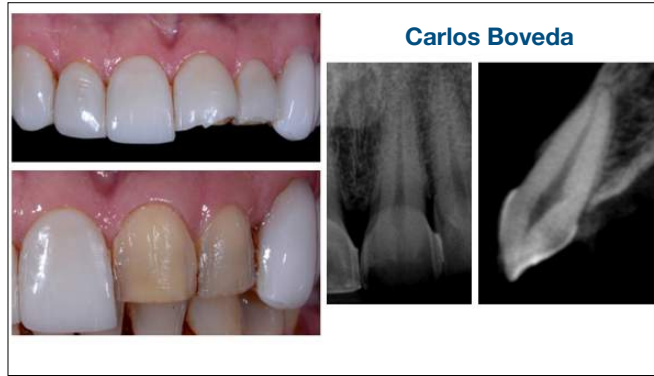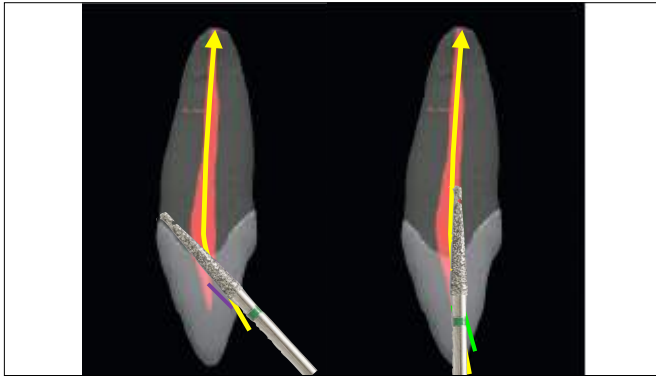
Minimale *invasieve* Endodontie





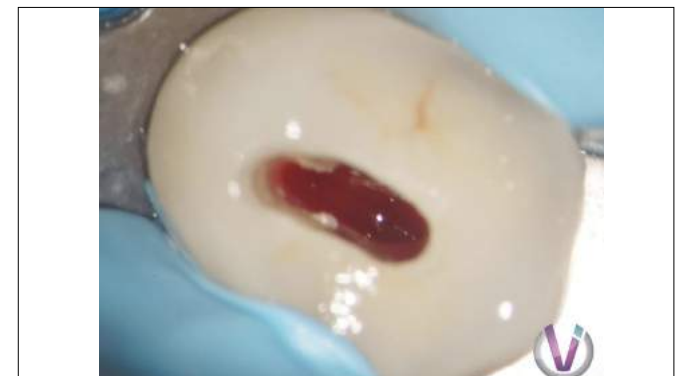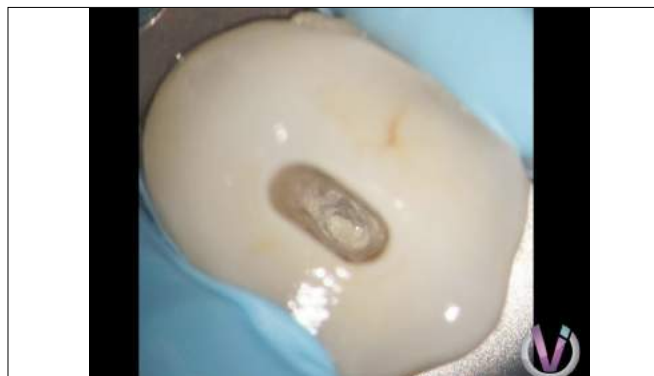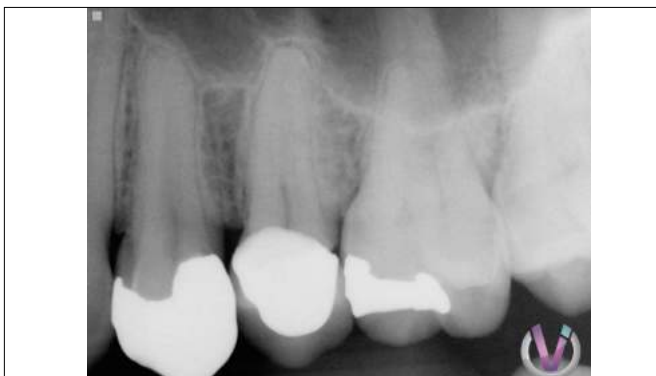**ENDODONTISCHE ANATOMIE
EN OPENEN
INCISIVEN**





**ENDODONTISCHE ANATOMIE EN
OPENEN**

PREMOLAREN



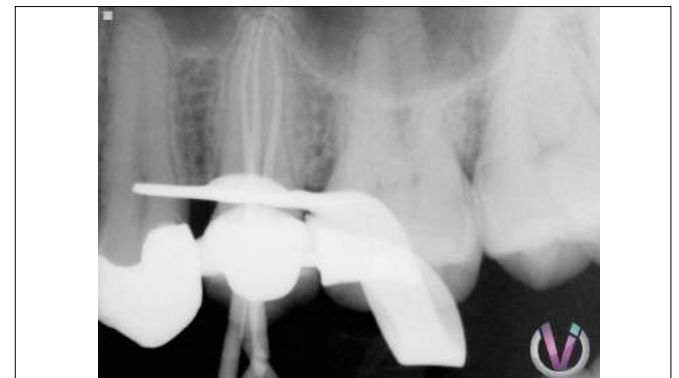
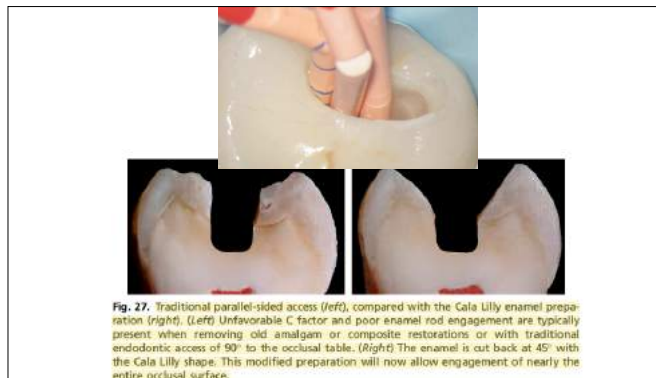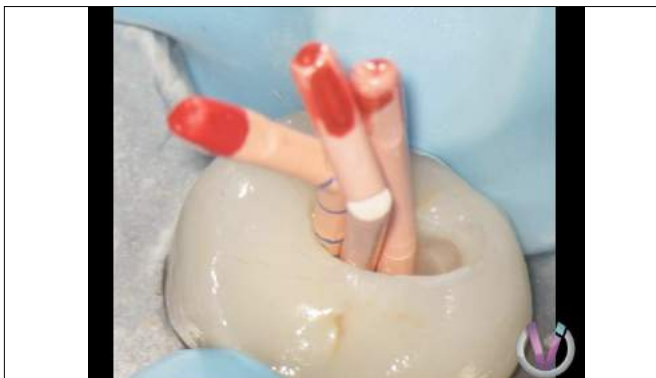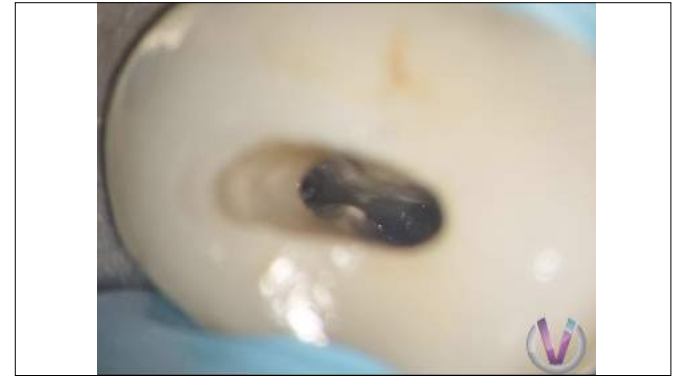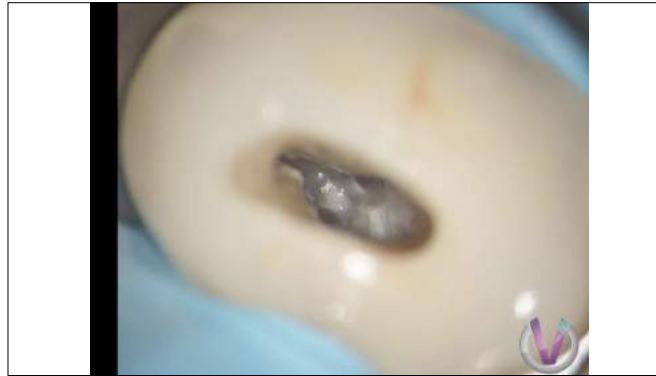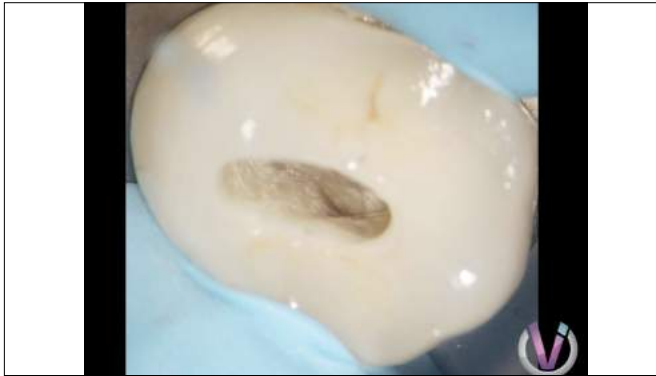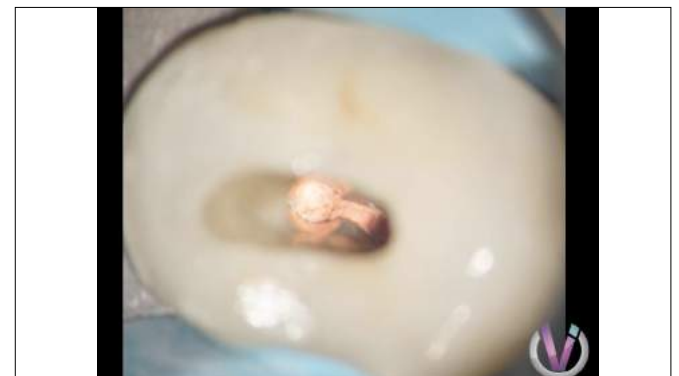
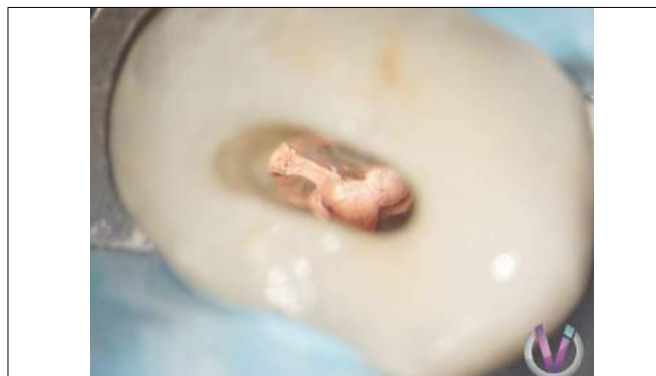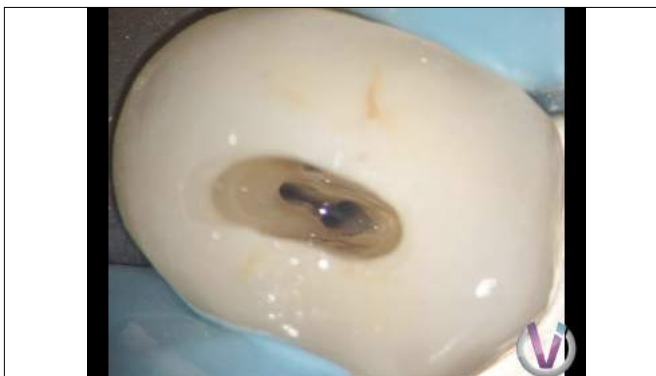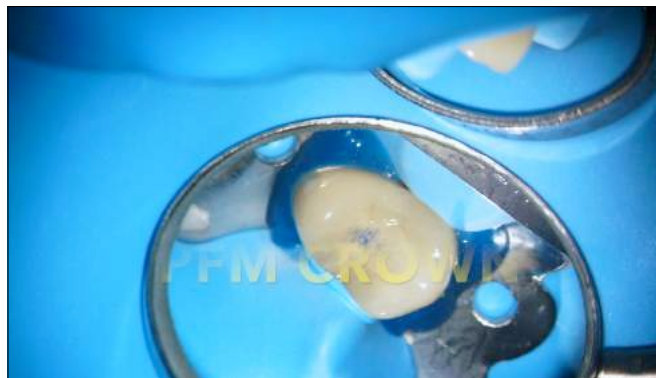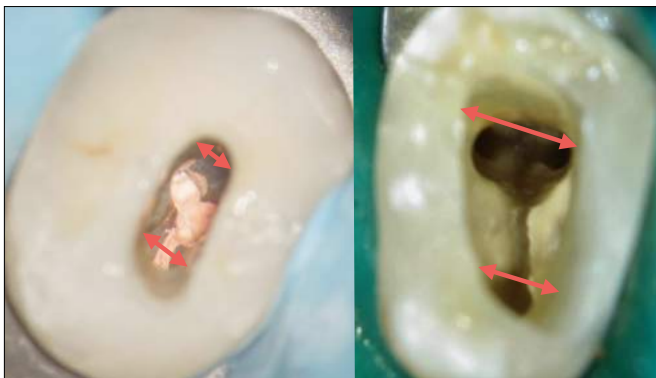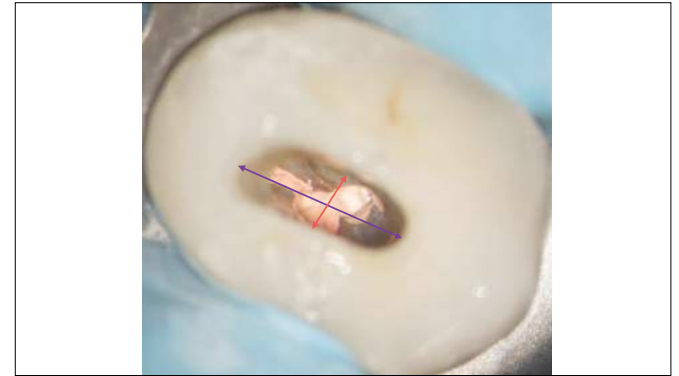
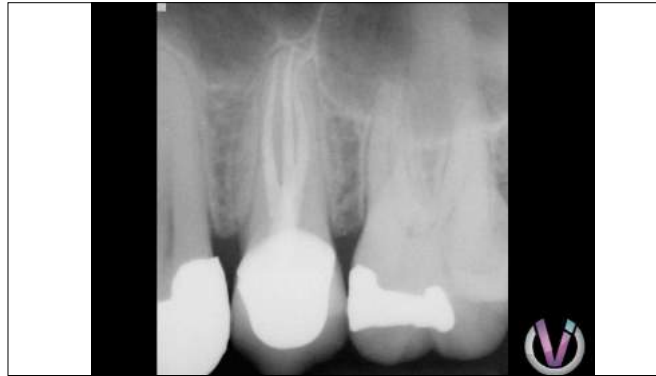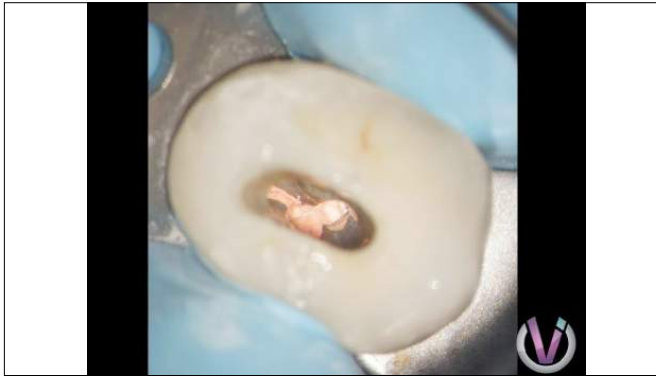


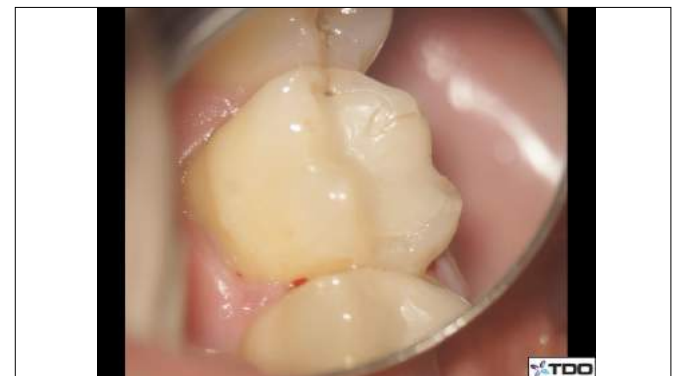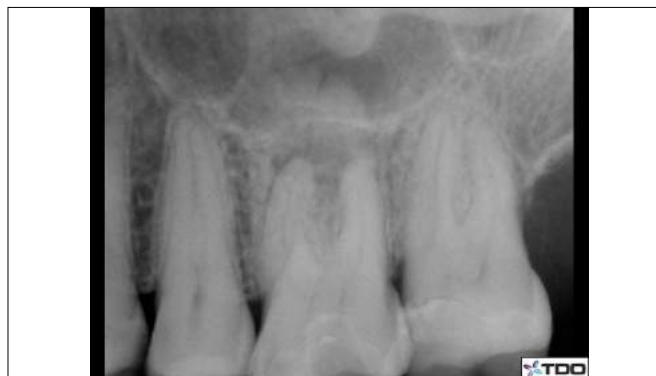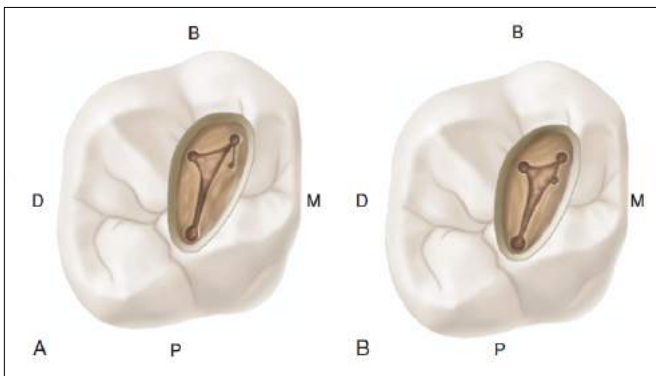
Fig. 27. Traditional parallel-sided access (left), compared with the Cala Lilly enamel preparation (right). (Left) Unfavorable C factor and poor enamel rod engagement are typically present when removing old amalgam or composite restorations or with traditional endodontic access of 90° to the occlusal table. (Right) The enamel is cut back at 45° with the Cala Lilly shape. This modified preparation will now allow engagement of nearly the entire occlusal surface.

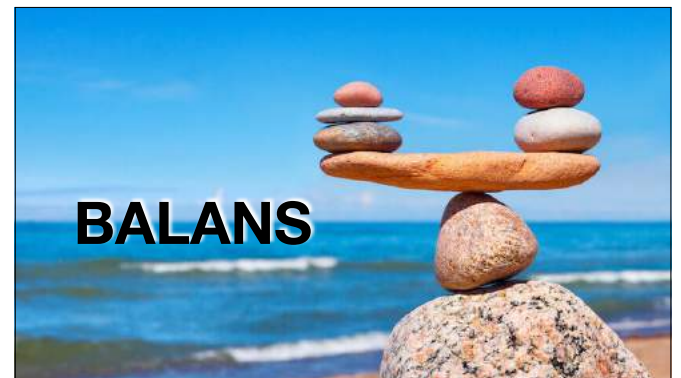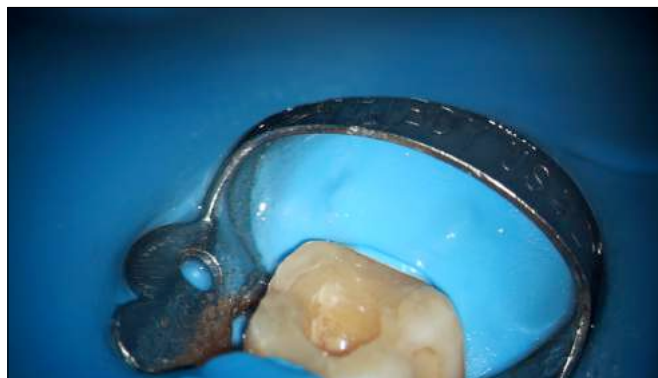
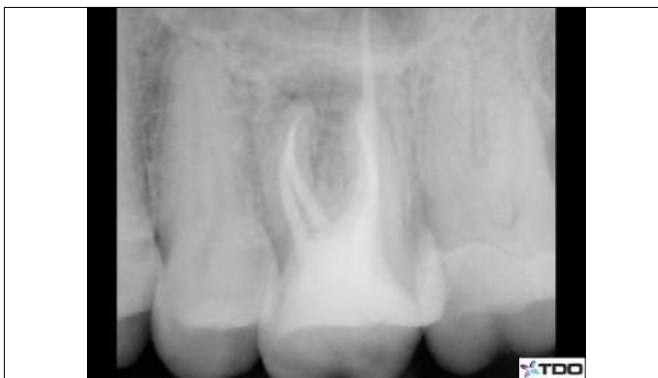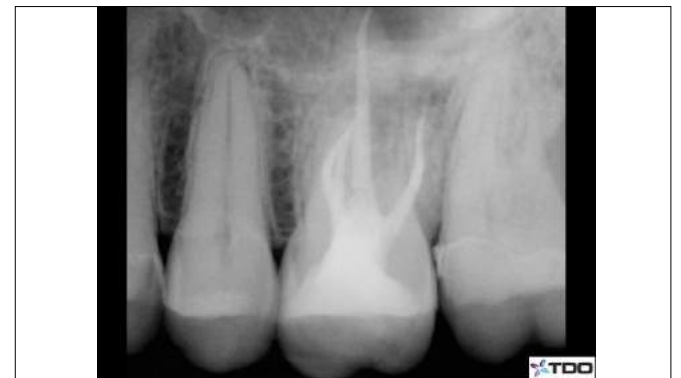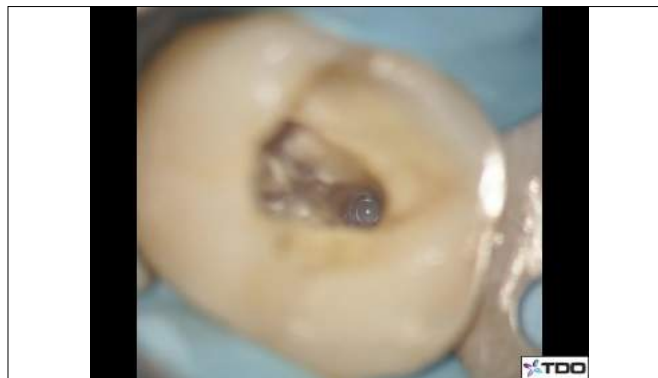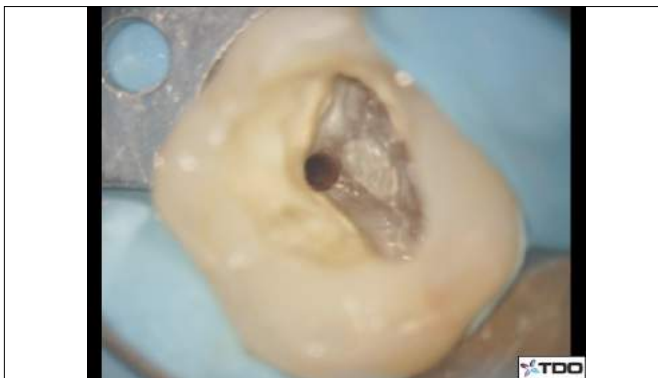
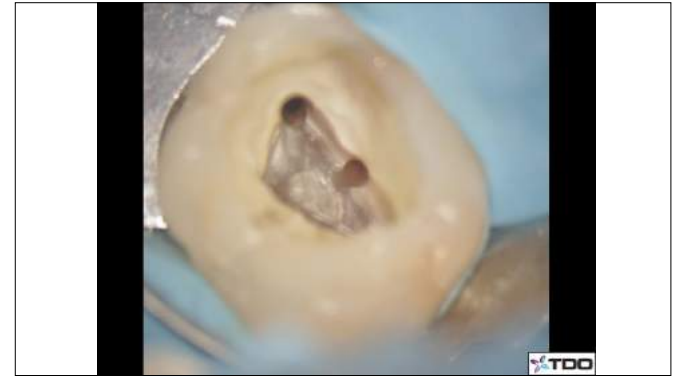




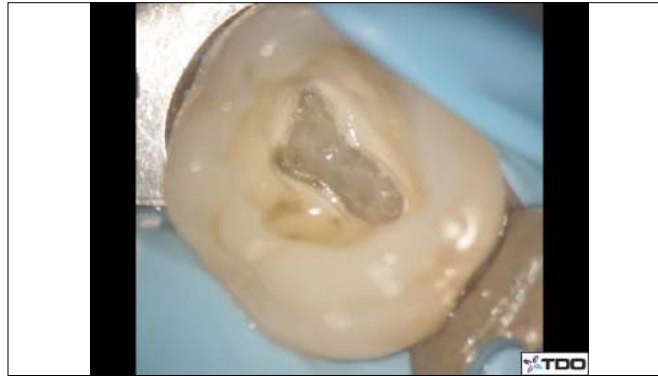
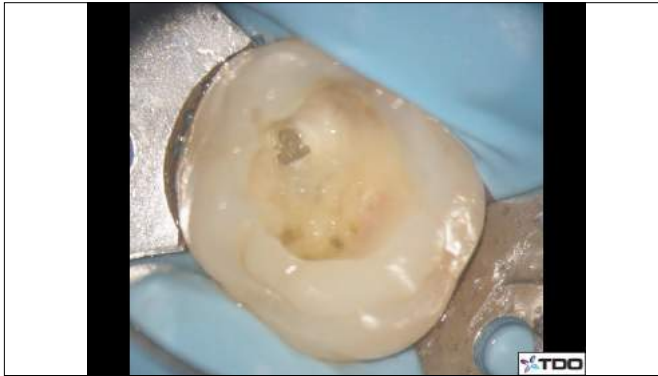**ENDODONTISCHE ANATOMIE EN
OPENEN**

MOLAREN







Kans van 1 op 1 miljoen
Er blijft bijna niets over